

---

# Intranasal Sinus Surgery: Revision Frontal Sinus Surgery Using Autologous Platelet Concentrate Enriched with Growth Factors (APC+)

**MARC M. KERNER, MD, FACS**

Assistant Clinical Professor of Surgery, UCLA School of Medicine  
18350 Roscoe Blvd., Suite 318, Northridge, CA 91325  
16550 Ventura Blvd., Suite 210, Encino, CA 91436  
(818) 349-0600 • E-Mail drkerner@marckernermd.com

---

## Introduction

Endoscopic frontal sinusotomy is a standard approach for dealing with chronic frontal sinusitis. Autologous platelet concentrate enriched with growth factors (APC<sup>+</sup>) is derived from the patients own blood. APC<sup>+</sup> has been shown to accelerate wound healing and enhance bone graft survival.<sup>1</sup> Few human studies have described its usefulness in soft tissue healing. We have presented data on its effectiveness and safety as a postoperative packing material in endoscopic sinus surgery.<sup>2</sup> APC<sup>+</sup> has excellent hemostatic properties, provides an excellent biologic dressing, and may prevent further synechiae formation within the sinuses.

The following case report describes a revision surgery for chronic left frontal sinusitis which was treated with endonasal endoscopic frontal sinus surgery using APC<sup>+</sup> to stimulate and accerate the wound healing process.

## Objective

A 60 year old female had undergone three prior surgical procedures for chronic sinusitis since 1987. She had persistent left frontal sinusitis due to recurrent stenosis of the left frontal nasal outflow tract. Prior to our evaluation, the patient was offered an open procedure including a frontal sinus obliteration and/or a transfacial frontoethmoidectomy. She elected to undergo another attempt at endonasal procedure.

## Materials and Methods

Approximately 50cc of intravenous blood was drawn pre-operatively and processed using an automated dual spin process (SmartPreP<sup>®</sup>, Harvest Technologies, Inc., Plymouth, MA). The 12 minute process produced 10cc of autologous platelet concentrate enriched with growth factors (APC<sup>+</sup>) and approximately 20cc of platelet poor plasma (PPP).

The patient underwent an endoscopic frontal sinusotomy using image guidance with the Instatrak system (VTI Systems, Boston, MA). Postoperatively, no packing was used except autologous platelet gel as a postoperative intrasinus dressing. An intraoperative view of APC<sup>+</sup> in the middle meatus at the completion of surgery is shown in Figure 1.

The patient was followed closely clinically in the postoperative period. Figure 2 shows the two week postoperative endoscopic view of surgical cavity in the region of the left frontal recess. The residual platelet clot is visible in the frontal recess region.

Figure 3 shows the endoscopic view of left frontal recess at 6 months. The mucosa is well healed with no visual evidence of infection or restenosis. At the 6 month follow-up, the patient also showed no clinical symptoms of chronic sinus infections and complete resolution of her facial pain. Long-term follow-up at 2 years revealed persistent patency of the left frontal sinus outflow tract.

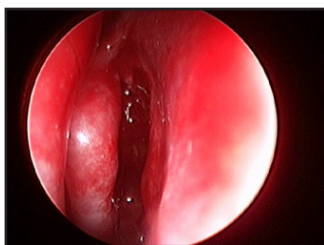


Figure 1

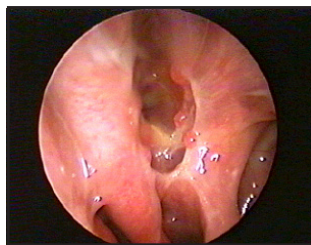


Figure 2

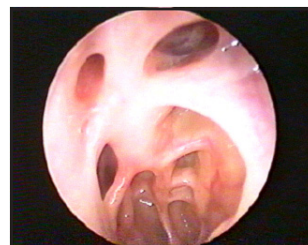

Figure 3

## **Discussion**

Endoscopic paranasal sinus surgery is the accepted modality for dealing with chronic sinusitis that has failed medical therapy. Our group has been using autologous platelet gel as an intranasal dressing for over two years and in over 175 similar procedures with excellent results<sup>2</sup>. We have found it to be an excellent hemostatic agent, reduces postoperative swelling, and it does not appear to lead to increased synechiae formation. These are all ideal qualities for a postsurgical dressing in sinus surgery. Our practice routinely uses APC+ to accelerate healing in otolaryngology procedures ranging from intranasal surgery to craniofacial surgery.

## **References**

1. Marx RE, Carlson ER, Eichstaedt RM, et al: Platelet rich plasma: Growth factor enhancement for bone grafts. *Oral Surg* 85:638, 1998.
2. Kerner MM. The use of autologous platelet gel as a postoperative dressing in endoscopic sinus surgery. Presented at the American Rhinologic Society, September 9, 2001, Denver, CO. (*in publication*)